

CASE REPORT



Reconstruction of the mandible with a free fibula flap in a male patient with a medication-related osteonecrosis using the CMX software

The Surgeons

Dr. Dr. F. Beiglboeck MD, DDS

Professor Dr. Dr J. Kleinheinz MD, DDS, PhD

Department of Cranio-Maxillofacial Surgery, University Hospital Münster, 48149 Münster, Germany

Dr. Dr. Beiglboeck is a double degreed specialist in oral and maxillofacial surgery. After completing his residency at the University Hospital in Basel, Switzerland, and at the University Hospital Muenster, Germany, he expanded his surgical skills in facial plastic and orthognathic surgery in São Paulo, Brazil. In 2023 he acquired additional qualifications in facial plastic surgery. Dr. Dr. Beiglboeck was particularly influenced by his work in Basel, Zurich and São Paulo and from his mentor Dr. Albino Triaca, who taughted him in chin-wing osteotomies and mandible distraction osteogenesis in orthognathic patients.

The Case



Patient Profile

In the present case, an 80-year-old male patient was referred to our department with a medication-related osteonecrosis of the jaw (MRONJ) – in this case of his mandible. The patient had been treated for multiple myeloma and metastatic prostate carcinoma with high doses of bisphosphonates for several years. The clinical picture initially showed stage I necrosis of the mandible according to the AAOMS (American Association of Oral and Maxillofacial Surgeons) MRONJ classification (1). The necrosis was primarily treated conservatively with a minor decortication and regular follow-up examinations, as the patient initially decided against surgery. Under this treatment, the patient showed a stable situation for more than 5 years. However, during the last consultations, a progression of the MRONJ of his mandible with a high risk of a pathological fracture was shown clinical and in the orthopantomogram as well in the computer tomography (CT). After the histopathological exclusion of metastasis in the mandible, a segmental mandibular resection with simultaneous reconstruction with a free fibula graft was decided together with the patient. For this purpose, a patient-specific reconstruction plate and cutting guides from Medartis CMX were customized under the supervision of Dr. Dr. F. M. Beiglboeck.



Clinical Findings/Preoperative Analysis

The orthopantomogram (Fig. 1) showed severe osteolysis, which extends to both mandibular angles and is related to medication-related osteonecrosis of the mandible. Clinically, it presented as stage III according to the MRONJ classification of the AAOMS (1). The patient's general status was stable and there were no signs of systemic inflammation.

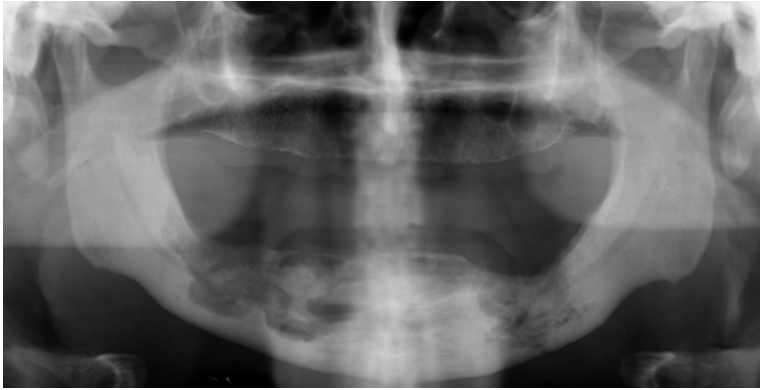
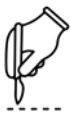

Fig. 1 – Orthopantomogram before histopathological exclusion of metastasis.

The mandible shows bilateral osteolysis, which almost involves the basal cortical bone.



Surgical Treatment

After a careful step-by-step briefing and informed consent for the surgery, virtual planning of the resection of the necrotic mandible and reconstruction with a fibula graft was followed. For this purpose, patient-specific cutting guides were customized for the resection of the mandible and harvesting of the fibula graft; finally, a patient-specific reconstruction plate for the mandible was virtually planned and manufactured (Fig. 3). After exposure of the fibula, the fibula osteotomy guide was fixed (Fig. 4). The harvesting was followed and the fibular segments were fixed to the patient-specific reconstruction plate (Fig. 5, Fig. 6). At the same time, the mandible was exposed, the mandibular osteotomy guides were fixed, and resection of the necrotic parts of the mandible was completed and preserved for histopathological analysis (Fig. 7). The fibular graft was then dissected of its vascular bundles and anastomosed to the facial vessels (A./V. facialis) by microsurgical technique. The continuity of the mandible was achieved by precise fit of the fibular graft and the patient-specific reconstruction plate using osteosynthesis (Fig. 8). For routine monitoring and control, the patient was admitted to the intensive care unit, and a postoperative CT was obtained (Fig. 9). After a couple of days in a regular ward, the patient was discharged to a rehabilitation clinic to improve his constitution.

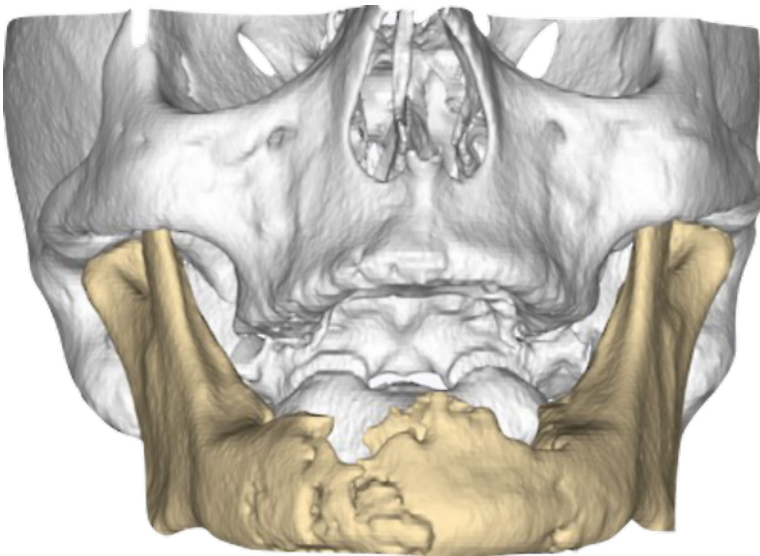


Fig. 2 – 3D reconstruction from the final CT scan; proof of severe osteolysis of the mandible with a high risk of a pathological fracture.

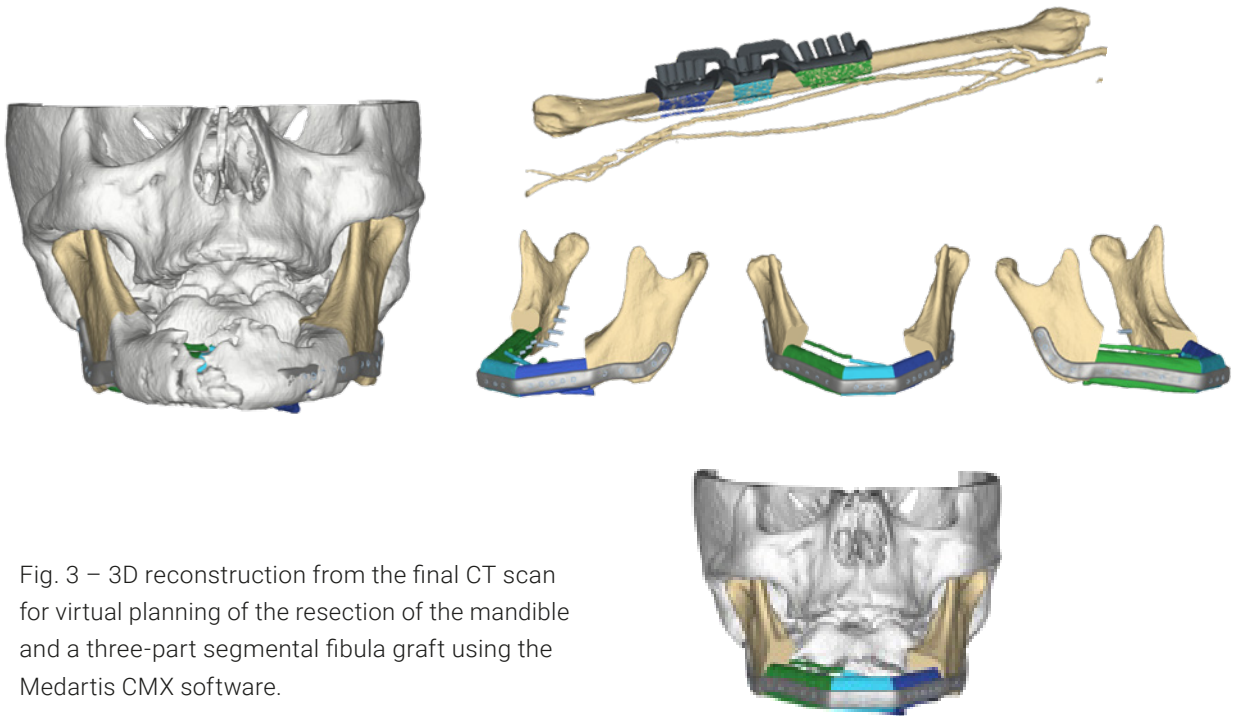


Fig. 3 – 3D reconstruction from the final CT scan for virtual planning of the resection of the mandible and a three-part segmental fibula graft using the Medartis CMX software.

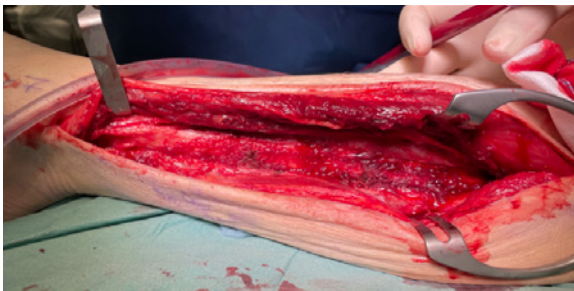

Fig. 4 a: Surgical approach to the fibula of the left leg




Fig. 4 b: Insertion of the patient-specific cutting guide to the fibula and fixation with SpeedTip screws

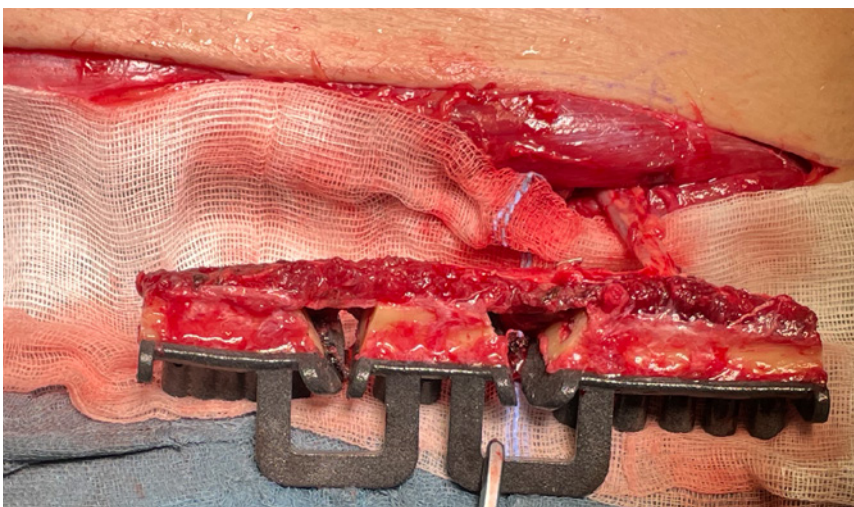


Fig. 5: The fibula flap was harvested and osteotomies were performed using the patient-specific cutting guide.

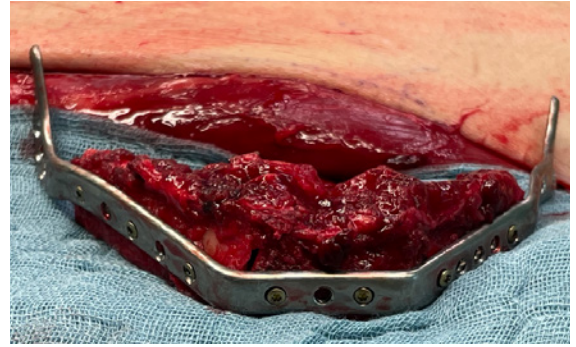
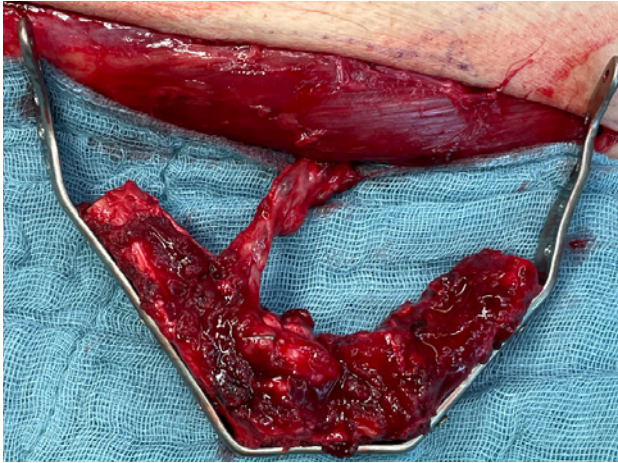


Fig. 6: The fibula segments were fixed with monocortical screws to the patient-specific reconstruction plate.

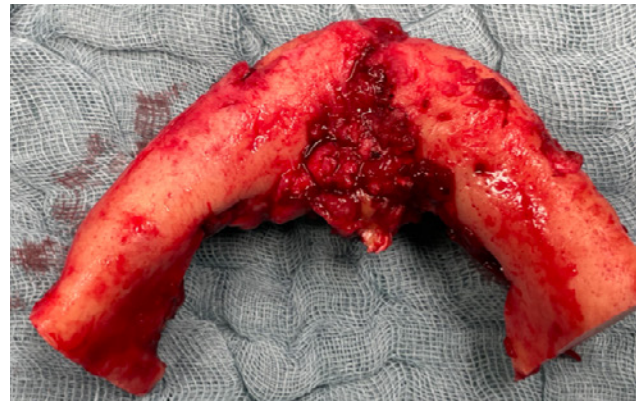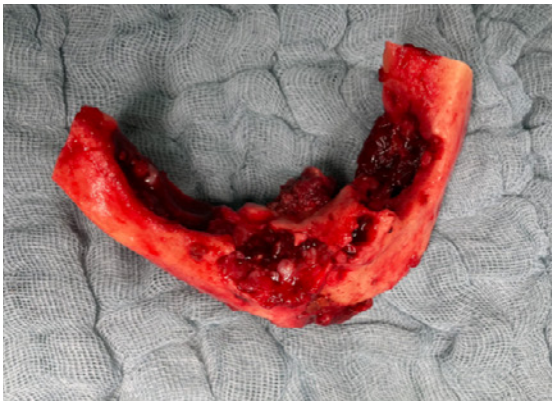
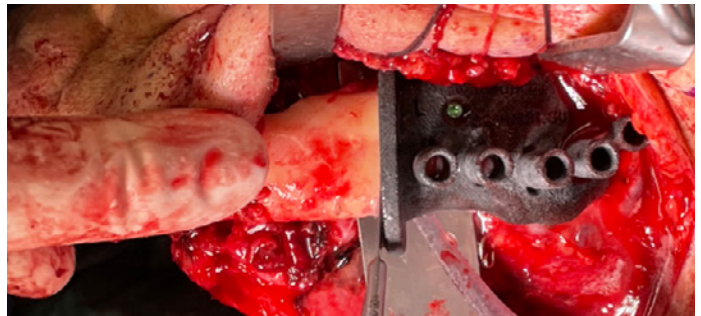
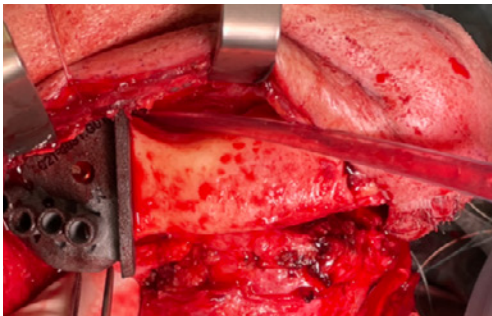


Fig. 7: a. Resection of the necrotic mandible bone (angle to angle) by patient-specific cutting guides
b. Coronal and basal view of the necrotic mandible bone

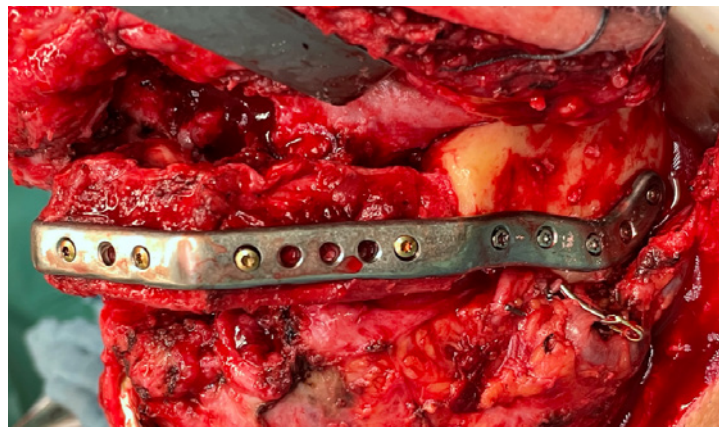
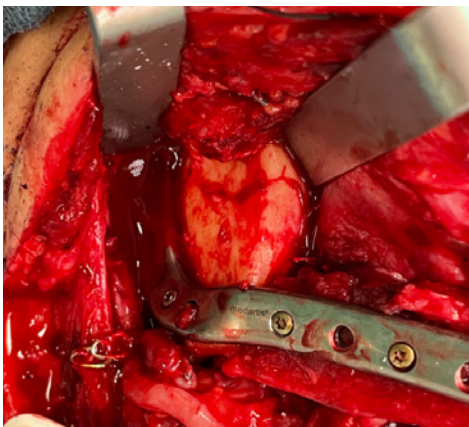


Fig. 8: After microvascular anastomosis, fixation of the fibula segments to the angles of the mandible via plate osteosynthesis.

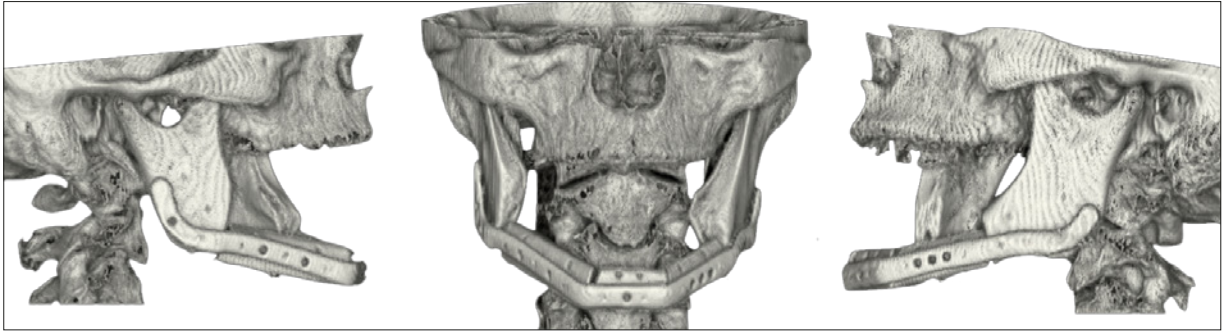


Fig. 9: Postoperative CT scan after partial mandibular resection with simultaneous reconstruction of a fibula graft.



Conclusion

MRONJ has become an integral part of the daily routine in maxillofacial surgery and needs a sufficient treatment strategy for every stage. In cases of large osteolysis affecting the mandible (stage III), segmental resection and reconstruction using a free fibula flap is usually recommended. This approach offers the opportunity for later dental rehabilitation in order to preserve the form and function.

The requirement for this type of reconstruction is a general health condition of the patient that allows this type of surgery, a sufficient vascular supply, which on the one hand does not impair vascularization at the donor site and guarantees sufficient nutrition for the graft, as well as simple and intuitive software for planning and reconstruction of the mandible as in this case with Medartis CMX.



References

- 1) Ruggiero SL. Reply: AAOMS Position Paper on Medication-Related Osteonecrosis of the Jaws-2022 Update. Diagnostic Milestones, Doubts, and Perspectives on MRONJ. J Oral Maxillofac Surg. 2022 Nov;80(11):1724. doi: 10.1016/j.joms.2022.07.150. PMID: 36332992.

Disclaimer: This case report presents the outcome of an individual patient case and it does not imply any guarantee or warranty in regard to treatment success. A surgeon must always rely on her or his own professional clinical judgment when deciding whether to use a particular product when treating a particular patient. The professional must always comply with the individual product's Instructions For Use (www.medartis.com/documentation/instructions-for-use) as well as all laws and regulations. Medartis is not giving any medical advice. The devices may not be available in all countries due to registration and/or medical practices. All content – such as texts, video and pictures – was created by healthcare professional mentioned in the case report. For further questions, please contact your Medartis representative (www.medartis.com). This information contains products with CE and/or UKCA marking.
For US only: Federal law restricts this device to sale by or on the order of a physician.

© Medartis 2023. Everything herein is protected by copyright, trademarks and other intellectual property rights, as applicable, owned by or licensed to Medartis or its affiliates unless otherwise indicated. It is forbidden to redistribute, duplicate or disclose, anything herein, in whole or in part, without the prior written consent of Medartis.

Case Report_Reconstruction of the mandible with a free fibula flap in a male patient with a medication-related osteonecrosis using the CMX software_2023-06

Medartis AG | Hochbergerstrasse 60E | 4057 Basel/Switzerland | www.medartis.com