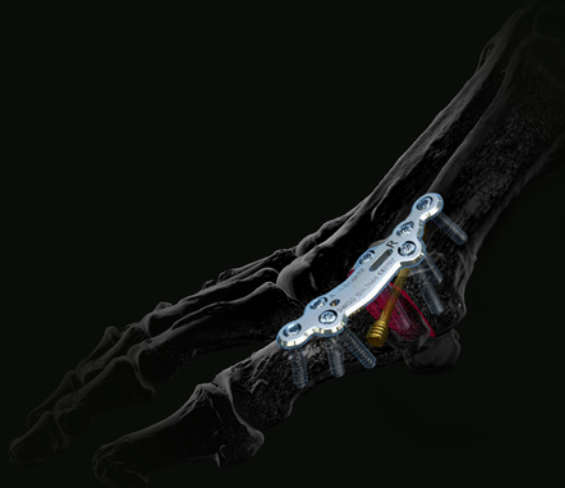



## CASE STUDY



# Treatment of severe hallux valgus and lesser ray lateral dislocations treated with a MTP1 fusion and P1 percutaneous osteotomies

## The Surgeon

### Jean-Luc Besse MD PhD

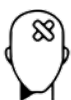Dr Jean-Luc Besse is an orthopaedic surgeon who has specialized in foot and ankle surgery, at the Lyon-Sud University Hospital, France.

Dr Besse graduated from the Alexis-Carrel Medical School–Lyon I University (1978-1984) and completed his residency in surgery, graduating in orthopaedic surgery and traumatology in 1989. He has achieved certification in biology and sport medicine, microsurgery and biology qualified in animal experimentation. From 1995-1999 he was an assistant professor and since then Hospital Practitioner in charge of foot and ankle surgery. He also has a PhD in Biomechanics/Biomaterials (Aix-Marseille II 1995), certification to direct research (Lyon 2005), and belongs to Lyon I IFSTTAR-LBMC UMRT-9406 Biomechanics research unit.

Dr Besse is past president (2011-2012) of the French Association of Foot Surgery (AFCP) and during his term, he was responsible for building the French Total Ankle Replacement Registry, which he still administers. He is also a member of the American Orthopaedic Foot and Ankle Society (AOFAS), and the education committee chairman of the European Foot and Ankle Society (EFAS).

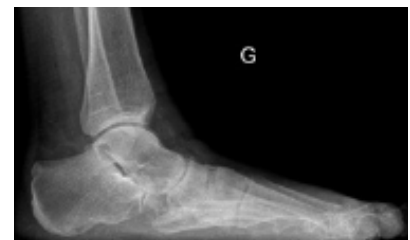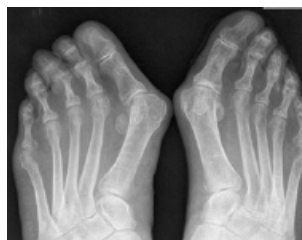He has published 93 peer-reviewed articles, participated in over 70 book chapters, and received three awards for his published work.

## The Case



### Patient History

An 85-year-old female with bilateral severe hallux valgus and associated lesser ray lateral dislocation. Due to an episode of soft corn ulceration on the 2nd toe medially we proposed a surgical treatment on the left foot, in spite of very old age.

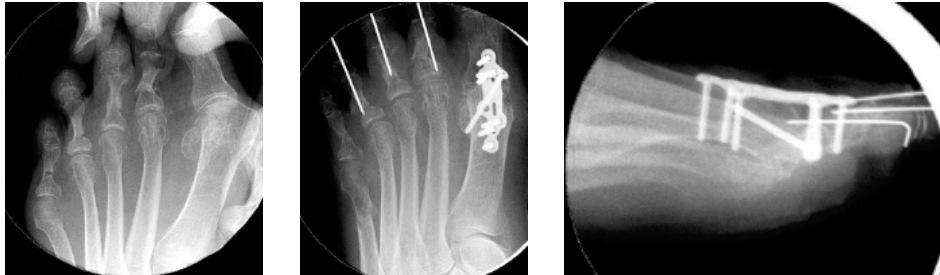


Figures 1–2: Preoperative AP WB view (left side: M1P1 60°, M1M2 10°, 234 toe lateral) and lateral WB view



### Surgical Treatment

Through a medial approach, we performed an MTP1 arthrodesis and implanted a Medartis APTUS MTP-1 fusion locking plate (4 locking screws and 2 cortical screws) and an oblique metatarsophalangeal screw. (ref. 1–2). Due to the age of the patient, we preferred a “cosmetic correction” of lateral toe dislocations with percutaneous P1 osteotomies of the lateral toes without metatarsus adductus treatment and bunionette correction with a percutaneous M5 osteotomy.



Figures 3–5: Intraoperative radiographic control

- AP view checking the position of the MTP-1 fusion plate and the first ray
- sagittal view monitoring the dorsiflexion of MTP1 fusion



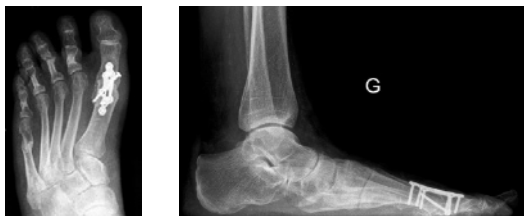### Postoperative Treatment

Full weight-bearing is started immediately with a stiff-soled rocker-bottom shoe worn for 6 weeks.



### Conclusion

At 4 months follow-up, the patient is satisfied with the MTP1 correction arthrodesis (valgus 12° - DF 22° - M1M2 5°). We advised the same surgery for the right side (M1P1 45°, M1M2 9°) without waiting for expected skin degradation.



Figures 6–7: Postoperative WB X-rays at 4 months



### References

- 1) Dalat F, Cottalorda F, Fessy MH, Besse JL. Does arthrodesis of the first metatarsophalangeal joint correct the intermetatarsal M1M2 angle? Analysis of a continuous series of 208 arthrodeses fixed with plates. *Orthop Traumatol Surg Res.* 2015 Oct;101(6):709-14. DOI: 10.1016/j.otsr.2015.06.021.
- 2) Gaudin G, Coillard JY, Augoyard M, Tourné Y, Meusnier T, Beaudet P, Bernard JN, Augoyard R, Besse JL; French Association of Foot Surgery (AFCP). Incidence and outcomes of revision surgery after first metatarsophalangeal joint arthrodesis: Multicenter study of 158 cases. *Orthop Traumatol Surg Res.* 2018 Dec;104(8):1221-1226. DOI: 10.1016/j.otsr.2018.08.011.

Disclaimer: This information is intended to demonstrate the Medartis portfolio of medical devices. A surgeon must always rely on her or his own professional clinical judgment when deciding whether to use a particular product when treating a particular patient. Medartis is not giving any medical advice. The devices may not be available in all countries due to registration and / or medical practices. For further questions, please contact your Medartis representative ([www.medartis.com](http://www.medartis.com)). This information contains CE-marked products. For US only: Federal law restricts this device to sale by or on the order of a physician.

Medartis AG | Hochbergerstrasse 60E | 4057 Basel / Switzerland | [www.medartis.com](http://www.medartis.com)

Treatment of severe Hallux valgus, lesser ray lateral dislocation treated by MTP1 fusion, P1 percutaneous osteotomies\_2022-07